

Intraoperative Incidental Discovery of Pinworms in Paediatric Appendectomy: A Case Report

DAKSHAYANI S NIRHALE¹, A KAVYA², PUSHKAR GALAM³, MAHENDRA WANTE⁴, ANKIREDDYPALLE SHANMUKHA SHASHANK REDDY⁵



ABSTRACT

One of the most common surgical emergencies worldwide is acute appendicitis. The inflammation of the appendix typically results from luminal obstruction, with faecoliths being the most prevalent cause. However, other aetiologies, such as parasitic infections, tumours, foreign bodies and lymphoid hyperplasia, can also lead to appendicitis. *Enterobius vermicularis*, frequently referred to as pinworm, is one of the most commonly encountered parasites associated with appendiceal inflammation. The following case report presents a case of acute appendicitis in an eight-year-old boy who experienced pain in the Right Iliac Fossa (RIF). This condition was managed by a laparoscopic appendectomy, during which the presence of pinworms was incidentally discovered intraoperatively and later confirmed by histopathology. This case emphasises the need to include parasitic infections in the diagnostic evaluation of children presenting with acute abdominal pain. The incidental discovery of pinworms during surgery underscores the necessity for thorough intraoperative evaluation and appropriate management to prevent complications.

Keywords: Acute appendicitis, Enterobiasis, *Enterobius vermicularis*, Laparoscopic appendectomy, Parasitic infections

CASE REPORT

An eight-year-old male child presented to the outpatient clinic with right-sided lower abdominal pain. The abdominal pain initially started as diffuse discomfort around the umbilicus but gradually localised to the right lower quadrant over the past 24 hours. The pain was described as sharp and intermittent, exacerbated by movement, and accompanied by anorexia. The patient denied having fever, nausea, vomiting, diarrhoea, or anal pruritus.

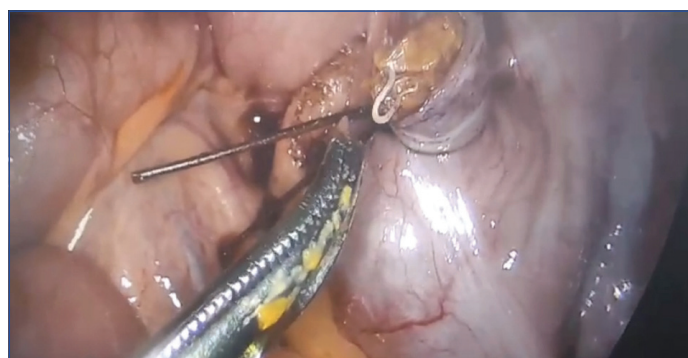
On physical examination, there was tenderness in the RIF, and Rovsing's sign was positive. There were no signs of peritoneal irritation and no palpable masses. Bowel sounds were present on auscultation. Laboratory investigations were normal, except for mild leukocytosis and mildly elevated C-Reactive Protein (CRP) levels.

Ultrasound of the abdomen and pelvis revealed a blind-ending, non compressible tubular structure in the RIF region with a maximum wall-to-wall diameter of 7.2 mm, along with surrounding periappendiceal fat stranding, consistent with acute appendicitis.

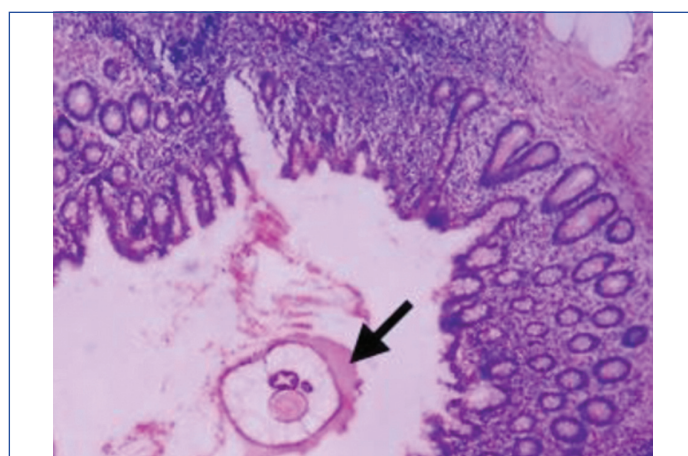
A diagnosis of acute appendicitis was established based on the patient's clinical assessment and diagnostic imaging findings, and the patient was taken for an emergency laparoscopic appendectomy. Intraoperatively, the appendix was visualised and found to be macroscopically inflamed and oedematous. After the appendix was transected between the endoloop ligatures, multiple pinworms were observed adherent to the mucosal surface of the appendix, causing luminal obstruction. Using a blunt grasper, all the worms were carefully extracted [Table/Fig-1].

The excised specimen of the appendix was sent for histopathological examination. Postoperatively, the patient was prescribed a single tablet of albendazole 400 mg orally, with a second dose given two weeks later. The recovery period was uneventful.

Histopathological examination of the appendix showed colonic mucosa with mucosal ulceration, suppuration, lymphoid hyperplasia, neutrophilic infiltrate, plasma cells and adult worm within the lumen. These worms showed thick cuticle, lateral alae and visible organs, which were typically consistent with *Enterobius vermicularis* [Table/Fig-2]. After two months of follow-up, the patient was asymptomatic.



[Table/Fig-1]: Midway through the dissection of the appendix, several macroscopically apparent worms were adhered to the mucosa.



[Table/Fig-2]: Microphotograph of colonic mucosa showing mucosal ulceration, suppuration, lymphoid hyperplasia, neutrophilic infiltrate, plasma cells and adult worm in lumen showing thick cuticle, lateral alae and visible organs (arrow), (H&E, 400x).

DISCUSSION

Previously known as *Oxyuris vermicularis* or oxyurides, *E. vermicularis* is commonly known as pinworm. It is a small, white, obligatory nematode that infects one billion people worldwide [1]. Pinworm infestation is the most prevalent helminthic infection, with an incidence of up to 50% in children and 20% in adults. It is usually

discovered by accident in the appendix of children aged 7 to 11 years [2]. Arca MJ et al., in a study examining appendectomy specimens, found *E. vermicularis* in 1.4% of cases, with a subset presenting with acute appendicitis symptoms [3]. Humans acquire the infection through faecal-oral transmission, either through self-inoculation, where eggs are transferred to the mouth via contaminated hands after scratching the perianal region, or through contact with eggs found in the environment, including contaminated surfaces, clothing, and bedding. The eggs hatch within the stomach following ingestion, and the emerging larvae assume a coiled form [4]. After passing through the cecum, larvae develop into adult pinworms, which are approximately one centimeter long. Adult gravid female worms move to the perianal region at night and lay up to 11,000 eggs. Embryonated eggs of *E. vermicularis* range in size from 30 to 60 µm. Six hours after oviposition, the eggs become infectious. The life cycle of *E. vermicularis* ranges from 11 to 35 days [4]. Although they can be seen in the lumen of the appendix, adult worms are primarily found in the ileum and ascending colon [5]. Among the paediatric population, there is a female preponderance in *E. vermicularis* appendicitis, which has a reported incidence ranging considerably from 0.2 to 41.8%; however, the reason behind this is yet unknown [5,6]. While the precise role of *E. vermicularis* in the development of appendicitis remains unclear, the luminal obstruction caused by the parasites is a potential contributing factor. Infections with pinworms can cause symptoms similar to appendicitis, even when no acute inflammation is observed histologically [7]. The pathophysiological correlation between *E. vermicularis* and clinically suspected appendicitis is comparable to those of appendicular faecolith or luminal lymphoid hyperplasia. It causes "appendicular colic," or colicky right iliac fossa discomfort, by blocking the appendicular lumen, but it also atypically causes appendicular inflammation [8,9]. Therefore, it may not always induce acute appendicitis, but it may result in a clinical setting that mimics it [6]. In young people, the elderly, and those of reproductive age, the diagnosis of appendicitis is still clinical and can be difficult, as a physical examination typically cannot distinguish between discomfort from a parasite and regular appendiceal pain. It is important to obtain a history of perianal irritation [10]. As the eggs and adult worms are not typically found in stools, a stool examination is not necessary [9]. Pinworm infection cannot be identified before surgery, even with high white blood cell counts or eosinophil levels. Radiological imaging, such as abdominal and pelvic ultrasound or abdominal and pelvic CT scan, can increase the certainty of the diagnosis in unclear circumstances, particularly in cases of suspected appendicitis [2]. Sosin M et al., presented the first reported ultrasound image of a pinworm in the appendiceal lumen [11]. Surgeons must be cognisant of the potential for pinworm infestation within the appendix, especially in paediatric patients with a history of perianal pruritus, and take precautions during the appendectomy procedure to prevent pinworm contamination of the abdomen. Cutting the appendix section by

section while maintaining traction can help avoid contamination of the abdomen. If worms leak into the abdominal cavity, endoscopic suctioning or diathermy must be used to remove them [12]. In this case, the initial imaging findings were suggestive of uncomplicated appendicitis, but the presence of pinworms was discovered only during surgical exploration. *E. vermicularis* is a curable infection that can be treated with standard oral anthelmintic medications, such as mebendazole, in individuals with RIF discomfort and suspected infection [6].

CONCLUSION(S)

One of the most common surgical emergencies worldwide is acute appendicitis, with faecoliths being the most typical cause. However, this case underscores the necessity of including parasitic infections such as *Enterobius vermicularis* in the diagnostic evaluation of acute abdominal pain, particularly in paediatric patients. The incidental discovery of pinworms during surgery emphasises the need for thorough intraoperative evaluation and appropriate management to prevent complications. This case highlights the clinical significance of recognising pinworm infestation as a potential cause of appendiceal obstruction and inflammation, contributing to a broader understanding of the aetiologies of acute appendicitis.

REFERENCES

- [1] Chaudhary R, Shukla A, Sharma K, Gupta A, Bansal M, Saurabh K. Pin worm causing acute appendicitis: Case report. Surg Curr Res. 2016;6(3):265.
- [2] Dunphy L, Clark Z, Raja MH. *Enterobius vermicularis* (pinworm) infestation in a child presenting with symptoms of acute appendicitis: A wriggly tale! Case Reports. 2017;2017:bcr-2017.
- [3] Arca MJ, Gates RL, Groner JJ, Hammond S, Caniano DA. Clinical manifestations of appendiceal pinworms in children: An institutional experience and a review of the literature. Pediatr Surg Int. 2004;20:372-75.
- [4] Panidis S, Paramythiotis D, Panagiotou D, Batsis G, Salonikidis S, Kaloutsis V, et al. Acute appendicitis secondary to *Enterobius vermicularis* infection in a middle-aged man: A case report. J Med Case Reports. 2011;5:01-03.
- [5] Antilaky JA, Akhoundi M, Belaloui M, Borovkov A, Marteau A, Bonte E, et al. Acute appendicitis caused by *Enterobius vermicularis*: Observations from a case report. IDCases. 2021;25:e01227.
- [6] El Bakouri A, Hajri A, Ettoussi A, Bouali M, Bensardi F, El Hattabi K, et al. Acute appendicitis secondary to *Enterobius vermicularis* infestation: A case report. Euro J Med Health Sci. 2020;2(2).
- [7] Mukherjee D, Naskar PK, Khatua M, Halder P. Pinworm infestation-induced appendicitis in children: A case report and literature review. Res Rev Pediatr. 2022;23(3):84-86.
- [8] Chitnis A, Azimi DY, Sabri S, Dhebri A. *Enterobius vermicularis*: A parasitic cause of appendicular colic. Cureus. 2020;12(6):e8524.
- [9] Hammood ZD, Salih AM, Mohammed SH, Kakamad FH, Omar DA, Hassan MN, et al. *Enterobius vermicularis* causing acute appendicitis, a case report with literature review. Int J Sur Case Reports. 2019;63:153-56.
- [10] Echevarria S, Rauf F, Hussain N, Zaka H, Ahsan N, Broomfield A, et al. Typical and atypical presentations of appendicitis and their implications for diagnosis and treatment: A literature review. Cureus. 2023;15(4):e37024.
- [11] Sosin M, Kent JR, Chahine AA. *Enterobius vermicularis* appendiceal colic. J Laparoendosc Adv Surg Tech. 2019;29(5):717-19.
- [12] Naalla R, Shetty P, Sud V. Worm in vermiform appendix: A surgeon's perspective. Case Reports. 2014;2014:bcr2014205411.

PARTICULARS OF CONTRIBUTORS:

1. Professor and Head, Department of General Surgery, Dr. D. Y. Patil Medical College, Hospital and Research Centre, Dr. D. Y. Patil Vidyapeeth, Pune, Maharashtra, India.
2. Postgraduate Resident, Department of General Surgery, Dr. D. Y. Patil Medical College, Hospital and Research Centre, Dr. D. Y. Patil Vidyapeeth, Pune, Maharashtra, India.
3. Assistant Professor, Department of General Surgery, Dr. D. Y. Patil Medical College, Hospital and Research Centre, Dr. D. Y. Patil Vidyapeeth, Pune, Maharashtra, India.
4. Professor, Department of General Surgery, Dr. D. Y. Patil Medical College, Hospital and Research Centre, Dr. D. Y. Patil Vidyapeeth, Pune, Maharashtra, India.
5. Postgraduate Resident, Department of General Surgery, Dr. D. Y. Patil Medical College, Hospital and Research Centre, Dr. D. Y. Patil Vidyapeeth, Pune, Maharashtra, India.

NAME, ADDRESS, E-MAIL ID OF THE CORRESPONDING AUTHOR:

Dr. A Kavya,
B49, Carnation Girls Hostel, Dr. D. Y. Patil Medical College, Hospital and Research Centre, Sant Tukaram Nagar, Pimpri, Pune-411018, Maharashtra, India.
E-mail: akavyareddy009@gmail.com

AUTHOR DECLARATION:

- Financial or Other Competing Interests: None
- Was informed consent obtained from the subjects involved in the study? Yes
- For any images presented appropriate consent has been obtained from the subjects. Yes

PLAGIARISM CHECKING METHODS: [Jain H et al.]

- Plagiarism X-checker: Feb 03, 2025
- Manual Googling: Feb 22, 2025
- iThenticate Software: Feb 25, 2025 (11%)

ETYMOLOGY: Author Origin

EMENDATIONS: 5

Date of Submission: Jan 29, 2025

Date of Peer Review: Feb 13, 2025

Date of Acceptance: Feb 27, 2025

Date of Publishing: Mar 01, 2025